

## An evaluation of the effect of a change in paranasal sinus volumes on the formation of nasal polyposis and mastoid aeration

Assessment of mastoid volume and paranasal sinuses volume

Nagihan Bilal<sup>1</sup>, Nursel Yurttutan<sup>2</sup>, Betül Kızıldağ<sup>2</sup>, Selman Sarica<sup>1</sup>, Saime Sağıroğlu<sup>3</sup>, Adem Doganer<sup>3</sup>, İbrahim Orhan<sup>1</sup>

<sup>1</sup>Department of Otorhinolaryngology, <sup>2</sup>Department of Radiology, <sup>3</sup>Department of Biostatistics and Medical Informatics, Faculty of Medicine, Kahramanmaraş Sutcu Imam University, Kahramanmaraş, Turkey

Presented at the 38<sup>th</sup> National Congress of Ear Nose Throat and Head Neck Surgery

### Abstract

**Aim:** It is thought that paranasal pneumatization could be a factor effective at the stage of nasal polyposis development. Pneumatization changes in the paranasal sinuses of those with nasal polyposis could affect mastoid aeration. Therefore, the aim of this study was to investigate any relationship between mastoid pneumatization and nasal polyps. **Material and Method:** Maxillary sinus, frontal sinus, mastoid and sphenoid pneumatization volumes were calculated based on paranasal sinus computed tomography (CT) images for a total of 133 patients, comprising 64 diagnosed with nasal polyposis and a control group of 69. **Results:** The left maxillary sinus and sphenoid sinus pneumatization values of the nasal polyposis patients were observed to be statistically significantly lower than those of the control group. A statistically significant positive relationship was found between mastoid pneumatization and maxillary, sphenoid and frontal sinus pneumatization in the nasal polyp group. **Discussion:** As a result of this study using the 3-D paranasal CT reconstruction method on patients with nasal polyposis, a reduction was determined in the pneumatization of mastoid air cells and maxillary sinus and sphenoid sinus pneumatizations. It can be considered that this reduction in sphenoid sinus and maxillary sinus pneumatization is a risk factor for nasal polyp development.

### Keywords

Nasal Polyp; Mastoid; Paranasal Sinuses; Three-Dimensional Imaging; Nasal Septum

DOI: 10.4328/JCAM.5871 Received: 11.04.2018 Accepted: 21.05.2018 Published Online: 22.05.2018 Printed: 01.03.2019 J Clin Anal Med 2019;10(2): 177-82  
Corresponding Author: Nagihan Bilal, Haydar Bey Mah. 32120. Sok. Beytepe Sitesi 4. Blok No:13 Kahramanmaraş, Turkey.  
GSM: +905052513618 F.: +90 3443004068 E-Mail: nagihanyazan@gmail.com  
ORCID ID: 0000-0002-2850-3481

## Introduction

Nasal polyposis (NP) is a chronic inflammatory disease, with a prevalence of 10% in the general population [1]. The pathophysiology of nasal polyposis has not yet been fully understood. It has been suggested that in the etiology of nasal polyps, several factors play a role, such as atopy, aspirin intolerance, chronic inflammation, vasomotor imbalance, Bernolli phenomenon, epithelial rupture, genetics, cystic fibrosis and infection [2].

The development of pneumatization in the mastoid and paranasal sinuses of mammals has been studied because many functions are undertaken including the humidification and management of airflow in respiration, the control of air inspired, the addition of resonance during phonation and the reduction of weight in the head [3,4]. The mastoid air cells and the paranasal sinuses are related to each other and pass through a similar pneumatization stage [5].

In recent studies using a 3D computer-based image reconstruction method, evaluations have been made of the paranasal sinuses, mastoid cells and the nasal cavity [5,6,7]. To the best of our knowledge, there has been no published study which has measured the maxillary, sphenoid and frontal sinus pneumatizations of patients with nasal polyposis using 3D computer-based image reconstruction.

A reduction in pneumatization of the paranasal sinuses in patients with nasal polyposis can be evaluated as associated with the pathophysiology of the disease. However, the incidence of nasal polyposis seen before the age of 20 years is low, with the mean age at which it is seen of 42 years [8], whereas paranasal pneumatization develops at the age of 10-15 years [9].

Therefore, the hypothesis of this study was that individuals with lower paranasal sinus pneumatization would be more predisposed to the development of nasal polyposis. Therefore, the maxillary, sphenoid and frontal sinus pneumatizations of patients with nasal polyposis were measured using 3D computer-based image reconstruction and the changes in these sinus pneumatizations were evaluated together with mastoid pneumatization.

## Material And Method

The study protocol was approved by the Local Ethics Committee and all procedures were applied in compliance with the Helsinki II Declaration. The patient consent forms are not available because this study was retrospective.

Over a period of two years, the medical records of 133 patients were examined. The study included 69 patients in the control group and 64 patients diagnosed with NP in the Otorhinolaryngology Department. According to the findings obtained in the study, the power for the sample size was 0.99. The exclusion criteria included previous middle ear surgery, a history of otitis media, otitis media with effusion or cystic fibrosis, those with antrochoanal polyps, a perforated tympanic membrane, or an atrophic or sclerotic tympanic membrane. Patients diagnosed with chronic otitis media and mastoiditis (abduction of the soft tissue in the ear with or without ossicles erosion, opacification of the mastoid air cells, and demyelination of the mastoid trabeculae, mucosal thickening) on computed tomography (CT) were also excluded from the study. The control group consisted of 69 patients who presented at the ENT clinic with various

rhinological complaints and for whom paranasal CT was requested for a diagnosis of septum deviation at the Otolaryngology Clinic, with age, gender, and septal deviation angles similar to those of the NP patients, but were not determined with NP chronic rhinosinusitis on paranasal CT. Axial and coronal two-planed paranasal CT scanning of all patients was performed with a 1 mm slice thickness. NP was assessed according to Lund-Mackay CT scores [10]. All the CT images were assessed by 2 radiologists.

The diagnosis of NP was made from the records of the patient examination and from CT imaging in accordance with the EOPOS 2012 guidelines [11]. Accordingly, the patients included in the study were those with a longer than 12-week history of nasal blockage / congestion / obstruction or nasal discharge or facial pain / pressure of reduced sense of smell / in addition to the symptoms of loss, endoscopic findings of nasal polyps and/or mucopurulent discharge from the central meatus and/or oedema or mucosal obstruction in the central meatus. Those with mucosal changes in the ostiomeatal complex and/or the sinuses seen on CT were included in the study.

## CT examination protocol

Paranasal sinus CT scanning was applied using a 16-detector-array CT device (Alexion, Toshiba Medical Systems, Nasu, Japan). Paranasal sinus and mastoid air cell volumes were calculated from thin-slice paranasal CT using multi-slice computed tomography (MSCT, Alexion, Toshiba Medical Systems, Nasu, Japan, 120 kV, 120 mAs). The parameters were scanfield of view (FOV) 250 mm (collimation: 64 x 0.625), and image matrix of 512 x 512. Following the scanning, the images were reconstructed and the paranasal sinus pneumatizations and the mastoid air cell pneumatizations were calculated on a workstation using the volume rendering technique (VRT) [12].

The images were analysed on a workstation (IntelliSpace Portal, Phillips Healthcare Nederland B.V., Best, Netherlands) by 2 radiologists with more than 10 years of CT experience. (Figure 1). The mastoid cells were identified territorially by drawing the boundaries of the mastoid air cells for each side. The measurement process lasted an average of 15 minutes for each patient. The measurements were calculated according to the Cavalieri principle [13]. The presence or absence of petrous apex pneumatization was also recorded.

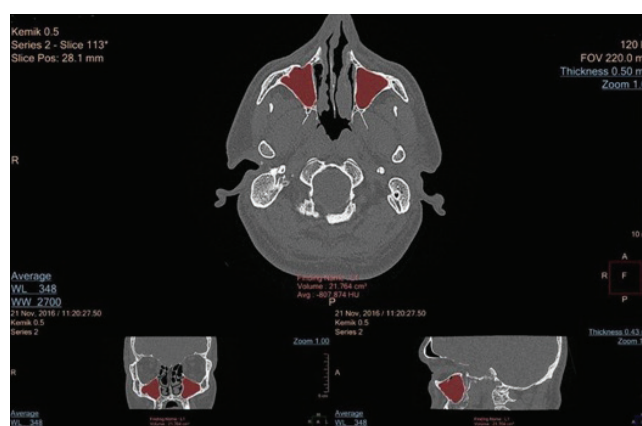

Figure 1. The measurements of both maxillary sinus volumes in three orthogonal planes.

The direction of septal deviation was based on the convex degree of the septal curvature. The angles were calculated between the lines extending from the maxillary spine toward the crista galli, and from the crista galli toward the section of the nasal septum with the most deviations. The septal curvature convex side defined the direction of the deviation [14] (Figure 2).

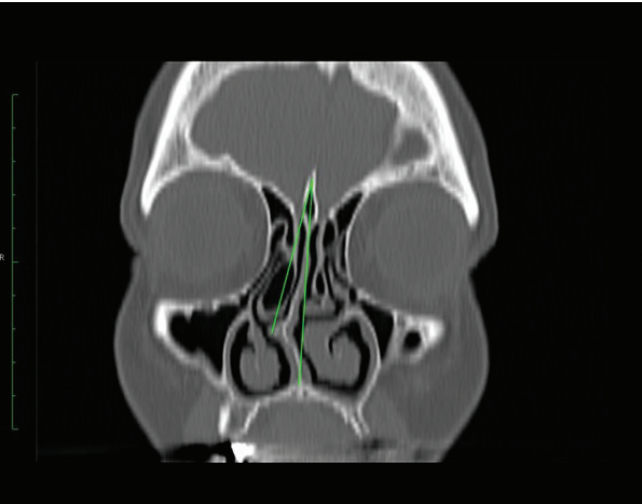


Figure 2. Calculation of septal deviation angle

Statistical comparison was made between the study and control groups in respect of age, gender, and septal deviation. The maxillary, sphenoid and frontal sinus pneumatization of the left and right sides of the patients and control groups were statistically compared separately. The mastoid pneumatization and the paranasal sinuses of the patient group were statistically compared separately in respect of pneumatization. Separate statistical comparisons were made of the mastoid pneumatization and the paranasal sinuses of the control group in respect of pneumatization.

Statistical Analyses

Analyses of the study data were made using SPSS software (SPSS, Chicago, IL). Continuous variables were given as mean ± standard deviation (SD), while the median (minimum and maximum values) and categorical variables were given as numbers and percentages. The materiality test of the difference between two averages was used in the comparisons of the independent group differences provided by the parametric test assumptions, while the independent samples T- test was used in the comparisons of the independent group differences not provided by the parametric test assumptions. Chi-square analysis was used in the comparisons of the categorical variables, while Spearman's correlation analysis was applied to evaluate the relationship between continuous variables. A value of  $p<0.05$  was accepted as statistically significant.

Results

The study sample consisted of 133 patients, 64 of whom were diagnosed with NP and 69 constituting the control group. The patient and control groups were similar in respect of age and gender ( $p=0.875$ ;  $p=0.516$  respectively). The average age of the group with nasal polyposis was  $47 \pm 14.37$  (min –max: 18-74) and the average age of control group

was  $43.31 \pm 14.25$  (min-max:20-76). The demographic data of both groups are shown in Table 1.

Table 1. Evaluations of the age and gender of the patient and control groups

Group	Age				t	P
	n	SD	Min	Max		
Group					0.160	0.873
NasalPolyp	47.00	14.37	18.00	74.00		
Control	43.31	14.25	20.00	76.00		
Group	Gender				Total	
	Male		Female		n	%
	n	%	n	%		
Group						
NasalPolyp	46	71.9	18	28.1	64	100.0
Control	46	66.7	23	33.3	69	100.0
Total	92	69.2	41	30.8	133	100.0

Chi-Squaretest;a:0.05 min: minimum max:maximum SD: StandardDeviation

In 22% of the patients, septal deviations were determined in the midline, 44% of which were deviated to the right and 34% to the left. In the control group, 16% of patients showed septal deviation, 42% of which were to the right and 42% to the left. The septal deviation angle was  $6.11^\circ \pm 3.07^\circ$  in the NP group, and  $6.21^\circ \pm 2.89^\circ$  in the control group. The difference in septal deviation angle between the two groups was not statistically significant ( $p=0.864$ ). In the scoring of the NPs, the left side was determined as  $7.69 \pm 3.28$ , the right side as  $7.61 \pm 3.51$  and the total NP score as  $15.30 \pm 6.18$ . In respect of polyp grade, the two sides showed no statistically significant difference. A statistically significant negative correlation was determined between NP grade and the right-side sphenoid sinus pneumatization ( $r= -0.255$ ,  $p=0.042$ ).

The maxillary, sphenoid and frontal sinus pneumatization of the NP group and of the control group are shown in Table 2. The left-side maxillary sinus pneumatization was evaluated as  $13.56 \pm 6.94 \text{ cm}^3$  in the patient group and as  $16.30 \pm 8.01 \text{ cm}^3$  in the control group. A statistically significant difference between the two groups was determined ( $p=0.038$ ). The left sphenoid sinus pneumatization was  $4.20 \pm 3.02 \text{ cm}^3$  in the NP

Table 2. Comparison of the maxillary, sphenoid and frontal sinus volumes of both groups

	GroupStatistics					
	Group					
	NasalPolyp		Control		t	p
	Volume	SD	Volume	SD		
Right maxillary(cm³)	14.04	7.79	15.42	8.26	0.989	0.324
Leftmaxillary(cm³)	13.56	6.94	16.30	8.01	2.093	0.038*
Total maxillary(cm³)	13.80	6.50	31.71	15.85	1.711	0.088
Right sphenoid(cm³)	4.47	3.21	5.21	3.08	1.351	0.179
Leftsphenoid(cm³)	4.20	3.02	5.44	3.97	2.009	0.047*
Total sphenoid(cm³)	8.68	4.59	10.65	5.12	2.332	0.021*
Right frontal(cm³)	3.61	2.85	3.73	3.76	0.197	0.844
Leftfrontal(cm³)	4.02	3.47	4.66	3.87	0.997	0.321
Total frontal(cm³)	7.64	5.72	8.39	6.48	0.706	0.481

Independentsamples t-test; a:0.05;\* The difference between the groups was statistically significant. SD:Standard deviation

group and  $5.44 \pm 3.97 \text{ cm}^3$  in the control group ( $p=0.047$ ). The total sphenoid sinus pneumatization was measured as  $8.68 \pm 4.59 \text{ cm}^3$  in the NP group and as  $10.65 \pm 5.12 \text{ cm}^3$  in the control group, with the difference between the two groups determined to be statistically significant ( $p=0.021$ ) (Figure 3).

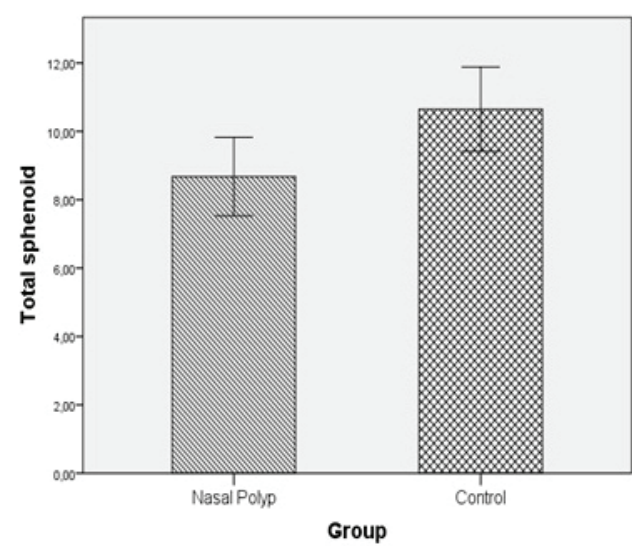


Figure 3. Evaluation with a box plot curve of the sphenoid sinus total dimensions of the nasal polyposis group and the control group.

The mean mastoid pneumatization volumes of the NP patient group and the control group are shown in Table 3. A statistically significant difference was observed between the two groups in the right and in the left mastoid pneumatization volume ( $p=0.001$ ;  $p=0.001$  respectively) (Table3). The overall average mastoid pneumatization volume was measured as  $6.25 \pm 4.38 \text{ cm}^3$  in the NP group and  $10.27 \pm 6.15 \text{ cm}^3$  (range 2.87–28.2) in the control group. A statistically significant difference was observed between the two groups ( $p=0.001$ ) (Figure 4).

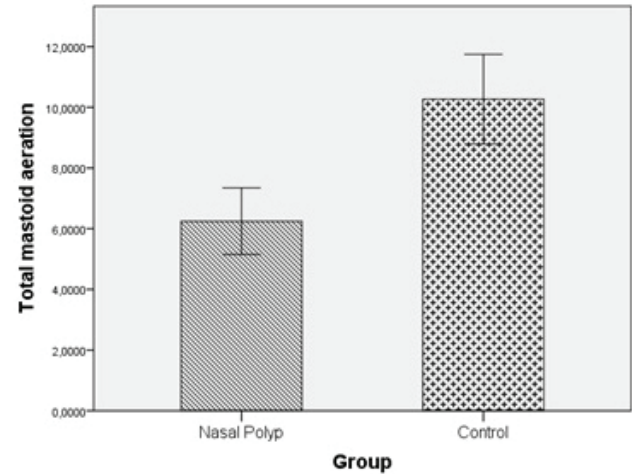


Figure 4. Evaluation with a box plot curve of the mastoid aeration volumes of the nasal polyposis group and the control group.

In the NP group a statistically significant positive relationship was determined between mastoid aeration and the maxillary, sphenoid and frontal sinus pneumatization. In the control group, a statistically significant positive relationship was determined between mastoid aeration and the maxillary and frontal sinus pneumatization.

Table 3. Comparison of the mastoid volume in both groups.

	Group							
	NasalPolyp			Control				
	N	Volume	SD	N	Volume	SD	t	p
Right mastoid aeration (cm³)	64	6.21	4.63	69	9.98	7.14	3.577	0.001*
Left mastoid aeration (cm³)	64	6.29	5.20	69	10.56	6.59	4.131	0.001*
Total mastoid (cm³)	64	6.25	4.38	69	10.27	6.15	4.313	0.001*

Independent samples t-test;  $\alpha:0.05$ ;\* The difference between the groups was statistically significant. SD:Standard deviation

Discussion

In this study, the left-side maxillary sinus, sphenoid sinus and frontal sinus pneumatization in the patients with nasal polyp-osis were statistically significantly smaller than those of the control group.

There are 2 hypotheses related to the difference between in-dividuals: the first is that pneumatization can be defined ge-netically and the second is that environmental factors, in other words, pathological events in childhood, can affect pneuma-tization [5]. Sinus pneumatization is completed in females by the age of 10 years and in males by the age of 15 years [9]. The pneumatization of mastoid air cells is completed with the development of petrous air cells and finishes in the pubertal period [15].

In those with low mastoid aeration and later ear infections, there is known to be an increase in the incidence of adhesive otitis and chronic otitis [9]. Similarly, low pneumatization vol-ume in the paranasal sinuses and the triggering of chronic inflammation may be a factor in the formation of nasal pol-yposis. Patients with maxillary hypoplasia or those with small dimensions may be predisposed to rhinosinusitis associated with malpositioning of the ostium location [16]. From another point of view, an infection in the period when pneumatization is continuing could be considered to cause both reduced pneu-matization and the formation of nasal polyposis. The decreased paranasal sinus pneumatization is thought to be the reason for rather than result of nasal polyp development, because pneu-matization has completed by the age of 18-20 years and the nasal polyps developed at a later age.

Due to the close anatomic relationship of the middle ear and the sinonasal cavity, disease in any localization of one, for any reason, affects the other [17, 18]. In a study of an elderly popu-lation by Hong et al, the frequency of chronic otitis media was found to be greater in those with chronic rhinosinusitis with nasal polyposis [17].

In the current study, the maxillary sinus pneumatization was measured as  $13.8 \pm 6.5 \text{ cm}^3$  in the nasal polyposis group and as  $15.85 \pm 7.27 \text{ cm}^3$  in the control group. In a study by Karakas et al, maxillary sinus pneumatization was measured as  $14.05 \pm 7.34 \text{ cm}^3$  [9]. In a study by Park et al, it was determined as  $14.83 \pm 1.36 \text{ cm}^3$  and by Aydın et al as  $15.1 \pm 4.6 \text{ cm}^3$  in patients with antrochoanalpolyposis and as  $12 \pm 3.5 \text{ cm}^3$  in the control group [6, 19]. In the current study, a smaller maxillary sinus volume was determined in patients with nasal polyposis.



The first research on mastoid pneumatization size was conducted by Diamant, who calculated an adult average of 12.07 cm<sup>2</sup> [20]. In a study conducted on 30 cadavers, Todd determined an average mastoid pneumatization volume of 7.59 ± 3.9 ml [21]. Sade reported mastoid pneumatization volumes of 12.9 ± 4 cm<sup>2</sup> in 150 normal ears and 17.4 ± 5 cm<sup>2</sup> in 150 otosclerotic ears [19]. Sato showed a significant difference in mastoid pneumatization volume between a group of 289 patients with chronic otitis media and a group of 73 patients with traumatic tympanic membrane perforation [22]. In a study by Kim et al. on correlations between the paranasal sinuses and mastoid air cells, mastoid aeration was found to be 13.231 cm<sup>2</sup> [5].

In the current study, the pneumatization of mastoid air cells was determined as 6.25 ± 4.38 cm<sup>3</sup> in the nasal polyposis group and as 10.27 ± 6.15 cm<sup>3</sup> in the control group. In literature, it has been thought that these differences could be associated with ethnic differences. In the current study, it was noticed that in general, the values of the control group were close to those reported in the literature. However, the mastoid pneumatization in the nasal polyposis group was determined to be lower. Studies in literature have observed a correlation between the sphenoid sinus and mastoid pneumatization [5,23]. This correlation was determined in both the control group and the nasal polyposis group of the current study. In the nasal polyposis patients with a small sphenoid sinus pneumatization, the left maxillary sinus pneumatization was also smaller than that of the control group.

Sphenoid sinus pneumatization was reported in studies by Amedee et al and Yonetsu et al as 7.5cm<sup>3</sup> and 8.2± 0.5 cm<sup>3</sup> respectively [24, 25]. Karakas et al measured the sphenoid sinus pneumatization as 8.71 ± 2.44 cm<sup>3</sup> [13]. In the current study, the total sphenoid sinus pneumatization was 8.68 ± 4.59 cm<sup>3</sup> in the nasal polyposis group and 10.65 ± 5.12 cm<sup>3</sup> in the control group. There was a statistically significant negative correlation between the sphenoid sinus right-side compartment pneumatization and the Lund-Mackay scores in the nasal polyposis group. Thus, a correlation was shown between an increase in polyp grading and a reduction in sphenoid sinus pneumatization. This finding supports the study hypothesis. It is expected that mastoid pneumatization will be affected in the same way in patients with less developmental sinus pneumatization [13]. As a consequence of our study, the result of reduced sinus pneumatization predisposing to nasal polyp development has emerged. And because of the correlation between pneumatization of the sinuses and the mastoid pneumatization in the developmental stage, it was concluded that decreased mastoid pneumatization has been observed in patients with nasal polyposis.

A limitation of this study was that it was cross-sectional in design. Further studies of longer duration and evaluating patients according to age groups would provide more meaningful data. In this study, a decrease was determined in maxillary, sphenoid and mastoid pneumatizations in patients with nasal polyposis, suggesting that individuals with a smaller maxillary sinus and sphenoid sinus pneumatization could be more predisposed to the formation of nasal polyposis. The study can be considered a guide for further studies of the pathologies and relationships between these areas using the 3-D CT image reconstruction method.

## Conclusion

In this study, using the 3-D CT image reconstruction method, a decrease was determined in the maxillary sinus, sphenoid sinus and mastoid air cells pneumatizations in patients with nasal polyposis. This reduction in sphenoid sinus and maxillary sinus volumes can be considered a risk factor for the development of nasal polyposis.

## Scientific Responsibility Statement

*The authors declare that they are responsible for the article's scientific content including study design, data collection, analysis and interpretation, writing, some of the main line, or all of the preparation and scientific review of the contents and approval of the final version of the article.*

## Animal and human rights statement

*All procedures performed in this study were in accordance with the ethical standards of the institutional and/or national research committee and with the 1964 Helsinki declaration and its later amendments or comparable ethical standards. No animal or human studies were carried out by the authors for this article.*

## Funding: None

## Conflict of interest

*None of the authors received any type of financial support that could be considered potential conflict of interest regarding the manuscript or its submission.*

## References

1. Remenschneider AK, D'Amico L, Gray ST, Holbrook EH, Gliklich RE, Metson R. The EQ-5D: a new tool for studying clinical outcomes in chronic rhinosinusitis. *Laryngoscope*. 2015; 125: 7–15.
2. Guven M, Karabay O, Akidil O, Yilmaz MS, Yildirim M. Detection of staphylococcal exotoxins in antrochoanal polyps and chronic rhinosinusitis with nasal polyps. *Otolaryngol Head Neck Surg*. 2013; 148: 302–7.
3. Scott-Brown WG, Kerr AG. Scott-Brown's otolaryngology. Head and neck surgery. Hodder Arnold, London. 2007; 1: 78-92.
4. Lee DH, Jun BC, Kim DG, Jung MK, Yeo SW. Volume variation of mastoid pneumatization in different age groups: a study by three-dimensional reconstruction based on computed tomography images. *Surg Radiol Anat*. 2005; 27: 37–42.
5. Kim J, Song SW, Cho JH, Chang KH, Jun BC. Comparative study of the pneumatization of the mastoid air cells and paranasal sinuses using three-dimensional reconstruction of computed tomography scans. *Surg Radiol Anat*. 2010; 32: 593-9.
6. Aydin S, Taskin U, Orhan I, Altas B, Oltay MF, Toksöz M et al. The analysis of the maxillary sinus volumes and the nasal septal deviation in patients with antrochoanal polyps. *Eur Arch Otorhinolaryngol*. 2015; 272: 3347- 52.
7. Orhan I, Ormeci T, Aydin S, Altin G, Urger E, Soylu E et al. Morphometric analysis of the maxillary sinus in patients with nasal septum deviation. *Eur Arch Otorhinolaryngol*. 2014; 271:727–32.
8. Erbek SS, Erbek S, Topal O, Cakmak O. The role of allergy in the severity of nasal polyposis. *Am J Rhinol*. 2007; 21:686-90.
9. Diamant M. The "Pathological size" of the mastoid air cell system. *Acta Otolaryngol*. 1965; 60: 1-10.
10. Lund VJ, Mackay IS. Staging in rhinosinusitis. *Rhinology* 1993; 31: 183–4.
11. Fokkens WJ, Lund VJ, Mullol J, Bachert C, Alobid I, Baroody F, et al. European position paper on rhinosinusitis and nasal polyps 2012. *Rhinology*. 2012; 23: 1-298.
12. Koc A, Ekinci G, Bilgili AM, Akpınar İN, Yakut H, Han T. Evaluation of the mastoid air cell system by high resolution computed tomography: three-dimensional multiplanar volume rendering technique. *J Laryngol Otol*. 2003; 117: 595-8.
13. Karakas S, Kavakli A. Morphometric examination of the paranasal sinuses and mastoid air cells using computed tomography. *Ann Saudi Med*. 2005; 25: 41-5.
14. Elahi MM, Frenkiel S, Fageeh N. Paraseptal structural changes and chronic sinus disease in relation to the deviated septum. *J Otolaryngol*. 1997; 26: 236–40.
15. Allam AF. Pneumatization of the temporal bone. *Ann Otol Rhinol Laryngol*. 1969; 78: 49–64.
16. Erdur O, Ucar FI, Sekerci AE, Celikoglu M, Buyuk SK. Maxiller sinus volumes of patients with unilateral cleft lip and palate. *Int J Ped Otorhinolaryngol*. 2015; 79: 1741–4.

17. Hong SN, Lee WH, Lee SH, Rhee CS, Lee CH, Kim JW. Chronic rhinosinusitis with nasal polyps is associated with chronic otitis media in the elderly. *Eur Arch Otorhinolaryngol.* 2017; 274: 1463-70.
18. Grote JJ, Kuijpers W. Middle ear effusion and sinusitis. *J Laryngol Otol.* 1980; 94: 177-83.
19. Park IH, Song JS, Choi H, Kim TH, Hoon S, Lee SH et al. Volumetric study in the development of paranasal sinuses by CT imaging Asian; A pilot study. *Int J Pediatr Otorhinolaryngol.* 2010; 74: 1347-50. Doi: 10.1016/j.ijporl.2010.08.018
20. Diamant M. Otitis and pneumatization of the mastoid bone. *Acta Otolaryngol. (Suppl)(Stockh)* 1940; 41.
21. Todd NW. Pars flaccida retraction and mastoid size: relationship in clinically normal specimens. *J Laryngol Otol.* 2007;121: 1020-4.
22. Sato Y, Nakano Y, Takahashi S, Ikarashi H. Suppressed mastoid pneumatization in cholesteatoma. *Acta Otolaryngol. (suppl)* 1990; 471: 62-5.
23. Hindi K, Alazzawi S, Raman R, Prepageran N, Rahmat K. Pneumatization of Mastoid Air Cells, Temporal Bone, Ethmoid and Sphenoid Sinuses. Any Correlation? *Indian Journal Otorhinolaryngol Head Neck Surg.* 2014; 66: 429-36. Doi: 10.1007/s12070-014-0745-z.
24. Amedee R. Sinus Anatomy and Function, In: Bailey BJ, Ed. *Head and Neck Surgery Otolaryngology.* Vol 1. Philadelphia: J.B. Lippincott Company. 1993; 342-9.
25. Yonetsu K, Watanabe M, Nakamura T. Age related expansion and reduction in aeration of shenoid sinus: volume assesment by helical CT scanning. *AJNR Am J Neuroradiol.* 2000; 21: 179-82.

**How to cite this article:**

**Bilal N, Yurttutan N, Kizildag B, Sarica S, Sağıroglu S, Doganer A, Orhan I. An evaluation of the effect of a change in paranasal sinus volumes on the formation of nasal polyposis and mastoid aeration. *J Clin Anal Med* 2019;10(2): 177-82.**